

Autopsy Case Of Head Injury In Decomposing Corpse

Reza Priatna¹, Adriansyah Lubis¹, Zulfia Retnanti Marissa¹

¹ Department of Forensic and Medicolegal, Medicine Faculty University of North Sumatra
RS. H. Adam Malik 20136, Medan, Indonesia.

DOI: 10.29322/IJSRP.12.10.2022.p13039
<http://dx.doi.org/10.29322/IJSRP.12.10.2022.p13039>

Paper Received Date: 5th September 2022
Paper Acceptance Date: 5th October 2022
Paper Publication Date: 13th October 2022

Abstract- Traumatology is the study of aspects of injury and its relationship to various types of violence. Injuries have become a major public health problem in all countries and most of them occur in developing countries. In the case of death from injury, head trauma is the most common type of trauma. Around 69 million people worldwide experience head injuries every year. Currently, the homicide rate is increasing. The target most often involved in murder cases is the head. The body of an adult male was found in a house. On examination, it was found that the wound was predominantly on the head. There is a fracture at the top of the skull. Infiltration of blood is seen in the inner scalp and meninges. Brain tissue liquefies due to decay. The cause of death is bleeding in the head cavity due to blunt trauma.

Index Terms- Head trauma, Brain Hemorrhage, Blunt Trauma.

I. INTRODUCTION

Wounds are one of the frequent cases that occur in life. Wound is a break in a continuity of any bodily tissue due to violence. Wounds can happen to living victims as well as the dead.¹ Wounds can be happen on the whole part of body human. However, most frequent deaths occur because of wound in the area of head. Head injury or traumatic brain injury defined as injuries involving skin of head, skull, and the bones that make up the face and brain.²

Traumatic brain injury is main reason of disability and death worldwide in individual with age under 45 years. In the United States from 1997 to 2007, total of patient who went to hospital and diagnosed as traumatic brain injury was 1,365,000 people a year, 275,000 people need to stay at hospital and numbers average death due to traumatic brain injury brain reach 52,000 people (18.4 per 100,000 population).³

There is a number cause of death by head injury. It can be occurs on brain tissue that cause contusion or laceration and blood vessels of the brain cause epidural, subdural, subarachnoid or intercerebral hemorrhage. If not handled quickly, will cause a number of secondary damage such as brain edema, brain ischemia, brain infection and increased of intracranial pressure which will lead to respiratory failure.⁴

Head injury has long been considered as the most common mechanics cause of death. Head injury also becomes most common cause of deaths in accident. Similar injury pattern could

caused by different mechanisms, while same mechanism could cause different injuries pattern.⁵

Linear fracture is the most common type of skull fracture, consisting of from 70%-80% head injury, and often related with accident like falls, while depressed fractures show more correlation with interpersonal violence.⁵

II. CASE REPORT

The male corpse sent by investigator with a letter to request Visum et Repertum. The corpse found inside a room in body condition is supine, covered blood and excrete bad smell. Only the victim stays at that home. The victim is 40 years old based on information from identity card.

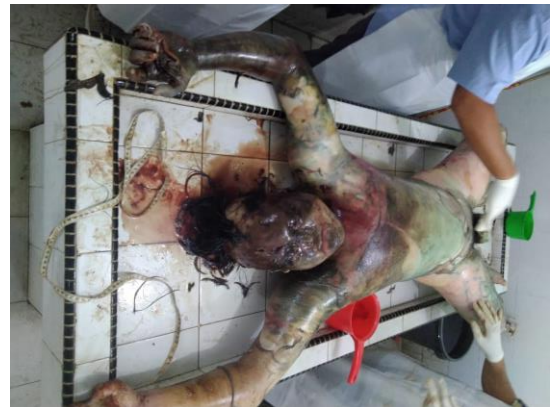

Image 1. Male corpse 40 years old in condition already on decay process.

External Examination

- The body is unlabeled and unsealed.
- Corpse wearing a t-shirt and short pants.
- No post mortem lividity and rigidity were found. Already found signs of decay like change of skin color, bulging on stomach, and bubbles of decay below the skin.
- Found maggots with largest size is 10mm.
- Corpse is a male, 166 cm length, the color of skin is yellow bright.
- Head:
 - Shape: symmetrical. Hair: straight, black, short hair.

- At the head, there are bruises colored dark red and swollen with size 5cm x 4cm.
- On the right side of forehead, there are 2 stab wound, size 4 cm and 6 cm long. Around wound, there are redness bruises.
- Eyes: right and left eyes comes out consequence of decay .
- Nose: symmetrical, bleeding from the right and left nostrils.
- Mouth: Tongue was bitten and sticking out.

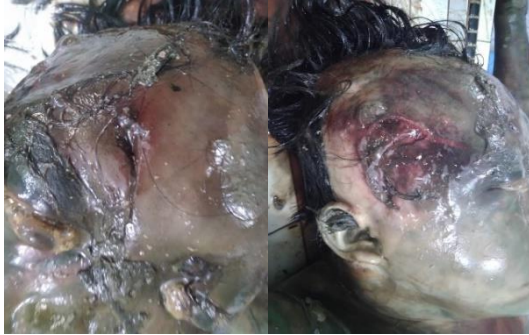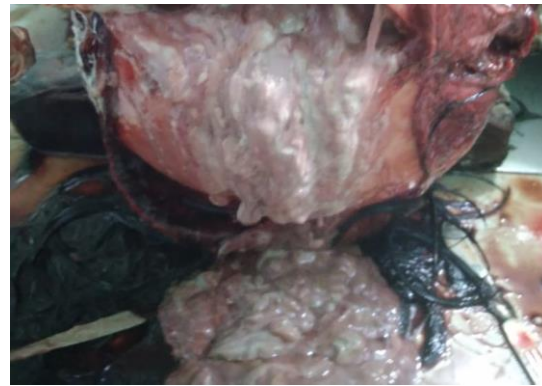

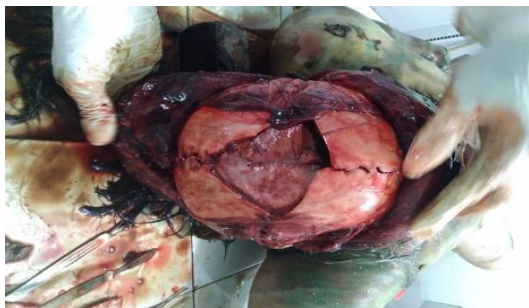
Figure 2. Stab wound on forehead

g. Stomach: looks bloated, there are no signs of violence.

Internal Examination

- chest cavity
 - Tardieu's spot on both lungs, chewy consistency, dark red color. Right lungs was 350 gr and left lung left was 300 gr
- Stomach Cavity
 - There is no food in the stomach.
 - There were no abnormalities in the small intestine, large intestine, pancreas, spleen and kidney.
- Cavity Head
 - On the inner surface of head skin, there were large area of blood absorption.
 - Skull suffered a comminuted fracture at the apex of the head, linear fracture of frontal bone to occipital bone.
 - **Figure 3.** Fracture of the skull
 - Brain tissue seen melt due to the decay process .



- **Figure 4.** Brain tissue that has melt as a result of the decay process

Conclusion on Visum et Repertum

1. The corpse is a male.
2. On external examination: There were signs of the decay process. A stab wound was found on the left side of the forehead due to sharp violence. Bruises with swelling on the top of the head due to blunt force.
3. On internal examination: There were bleeding spots in the lungs and heart, blood absorption on the inner side of the scalp, fractures in the skull, and blood absorption in piamater.
4. Estimated time of death of the victim is 2-4 days. The cause of death of the victim because of blunt trauma of the head that lead to cerebral hemorrhage.

III. DISCUSSION

The case above is a case of the body of an adult male in the house. According to the family, the victim lives alone in his house. From the examination of the body, several things were found. The first is the estimated duration of death of the victim.

As an forensics, we could not determine the time of death a person (*postmortem interval*) for sure. However, in tanatology, we could estimate the time of death by measuring corpse temperature, post mortem lividity, rigidity and decay process.⁶

In this case, we found decomposition processes such as a greenish discoloration of the skin of the abdomen, abdominal bulging, exfoliation of the epidermis and bubbles of decay below the skin were found in the bodies. This indicates that the estimated duration of death is more than 24 hours. In this case also found maggots with the largest length is 10 mm (instar II) so it can be concluded that the estimated death of the victim is 2-4 days.

Death is a process that can known by clinical through inspection from changes that occur in the body corpse. Symptom will could seen after a number of minutes, hours and so on. Lost oxygen can becomes reason of death. This thing because the obstacle of oxygen enter lungs (hypoxia).⁷ In this case we found a number of sign asphyxia like bluish on finger of the hands and feet. Internal examination shows petechiae in lungs and heart.

Injuries to the victim were more experienced in the head area. From the examination, injuries outside the head area were only found in the knees and lower legs. Injuries to the head are caused by sharp and blunt force. On the forehead, an open wound was found with flat wound edges, sharp wound angle and no tissue bridge. The characteristics of this wound are more towards sharp

violence. Sharp violence is divided into 2 types, namely stab wounds and incisional wounds. It could be that the death of the victim in this case was the result of blood loss from this open wound, but if seen from the other findings, one of which was a bluish fingertip, then this did not match. If the death is due to heavy blood loss, the fingertips should appear pale.

Signs of blunt trauma to the victim's head were seen on the top of the head where there was bruising and swelling. As with the bruises, on the inner side of the scalp layer was found extensive blood infiltration. Just below the bruise, a comminuted fracture was also found. The bone is split into several pieces which, if the shards are removed, will reveal a hole at the top of the head. From the front side of the orifice a linear fracture leading to the frontal bone was seen and from the back side of the orifice there was also a linear fracture leading to the occipital bone. From the shape of the fracture, it can be concluded that the cause of fracture is the result of blunt force. This is reinforced by the absence of lacerations on the scalp where the fracture is located.

On examination of the piamater found blood absorption. However, the brain tissue has melted due to the process of decay. Absorption of blood in the piamater indicates that intracranial hemorrhage has occurred leading to subarachnoid hemorrhage. However, it is possible that it can also be exacerbated by direct damage to brain tissue in the form of lacerations or brain bruises, considering the shape of the fracture which indicates the presence of a large amount of energy hitting the victim's head. However, due to the decay process, the complete macroscopic picture of the brain cannot be assessed.

Brain hemorrhage is one of the primary brain injuries. Concurrent primary injury with change metabolic and mobile trigger cascade biochemistry, causes secondary wave or secondary brain injury. Manifestation from secondary brain injury are cerebral edema and increased intracranial pressure. And if not handled with quick will make happening stem brain ischaemic so that result in respiratory failure.⁸

According to information from the police, the victim was found in the victim's room, lying on the floor. No tools were found which were thought to cause injuries to the victim's head. Therefore, it is very unlikely that the victim's death was caused by suicide or an accident. The criminal articles related to this case are about severe persecution resulting in death in Pasal 351 line (3) and Pasal 354 of the KUHP and murder case in Pasal 338 and 340 of the KUHP.

IV. CONCLUSION

This report contains cases of blunt force head injury with suspected homicide. On autopsy examination, it was found that there were signs of asphyxia with the cause of intracranial bleeding exacerbated by skull fractures due to blunt force and injuries to the head caused by sharp and blunt force. The criminal articles that can be imposed are acts of severe abuse that result in death in Pasal 351 line (3) and Pasal 354 of the KUHP or concerning murder in Pasal 338 and 340 of the KUHP.

REFERENCES

- [1] [1] Satyo AC. Aspek Medikolegal pada Forensik Klinik. Majalah Kedokteran Nusantara Vol 39 No 4; 2006.
- [2] [2] Snell RS. Clinical Anatomy for Medical Student (6th ed). Jakarta: EGC; 2006.
- [3] [3] Irianto K. Anatomi dan Fisiologi. Bandung: Alfabeta; 2012.
- [4] [4] Basmatika, I. SECONDARY BRAIN INJURY. E-Jurnal Medika Udayana, 444-464; 2013.
- [5] [5] Kranjoti E. Forensic investigation of cranial injuries due to blunt force trauma: current best practice. Research and Reports in Forensic Medical Science; 2015.
- [6] [6] Dix J, Graham M. Time of Death. Decomposition and Identification An Atlas. CRC Press LLC; 2000.
- [7] [7] Budiyo. Kematian Akibat Asfiksia Mekanik. Ilmu Kedokteran Forensik. Edisi 1. Jakarta: Fakultas Kedokteran Universitas Indonesia; 1997.
- [8] [8] Stippler M. Craniocerebral Trauma. Bradley's Neurology in Clinical Practices. London: Elsevier; 2015.

AUTHORS

First Author – Reza Priatna, Department of Forensic and Medicolegal, Medicine Faculty University of North Sumatra RS. H. Adam Malik 20136, Medan, Indonesia., Email: rjpr11111@gmail.com

Second Author – Adriansyah Lubis, Department of Forensic and Medicolegal, Medicine Faculty University of North Sumatra RS. H. Adam Malik 20136, Medan, Indonesia.

Third Author – Zulfia Retnanti Marissa, Department of Forensic and Medicolegal, Medicine Faculty University of North Sumatra, RS. H. Adam Malik 20136, Medan, Indonesia.